

## A CHRONIC BRONCHIAL FISTULA USING A POLYVINYL - ALCOHOL TUBE

A. A. Rogov

From the Prof. S. I. Chechulin Central Research Laboratory (Head -  
A. S. Chechulin, Scientific Consultant - Corresponding Member AMN  
SSSR Prof. A. I. Strukov) at the I. M. Sechenov First Moscow Order of  
Lenin Medical Institute

(Received September 30, 1958. Presented by Active Member AMN SSSR  
B. V. Petrovskii)

During the experimental investigation of various pathological conditions of the lung (atelectasis, acute and chronic bronchitis, bronchiectasis and so on) it is often necessary to make prolonged observations on the physiological processes developing in the lung. The existing methods for the experimental study of the pathology of the lungs are satisfactory for the solution of certain problems. These include, for example, the production of atelectasis in animals by obstruction of the bronchus by various foreign bodies [2, 3, 6] or the application of a ligature to the bronchus [1]; the production of fibrosis of the lung by ligation of the bronchial arteries [5] and of bronchitis, using various irritants for this purpose [4]. None of the classical methods, however, can be used for the functional investigation of the condition under study nor for continuous observations on a pathological process.

The most suitable method to be used for functional investigations of the lung in chronic experiments ought to be the formation of a chronic bronchial fistula. Attempts to use fistula tubes of metal, glass or rubber have, however, usually ended in failure, for sloughing has occurred at the site of suture of the tube and it has slipped out of the bronchus, and led to the development of pneumothorax and empyema. We have attempted to form a bronchial fistula using a plastic tube (polyvinylalcohol) as used in thoracic surgery for the repair of large vessels and which, by being sufficiently hygroscopic, do not cause sloughing.

### METHOD OF OPERATION\*

In the preoperative period a pneumothorax was gradually induced in the dogs in order to prevent pleuropulmonary shock. The operation was performed under intratracheal ether-oxygen anesthesia, after preliminary injection of morphine and thiopentone. Throughout the operation the animals received antishock fluid, given by A. F. Fatin's drip method.

The bifurcation of the trachea was approached from the left dorolateral aspect, by resection of the third and fourth ribs. After procaine infiltration of the posterior mediastinum, the left main bronchus was isolated and a T-shaped fistula tube, with a central obturator end, was inserted into a longitudinal incision in its membranous portion (Fig. 1). The tube was fixed into the bronchus by means of a silk purse-string suture, the ends of which were brought out in the paravertebral region and fixed to the skin. The operation wound was closed in layers. In the postoperative period penicillin solution was injected through the tube into the bronchus and intramuscularly for 7 days, and periodic drainage was undertaken. In three cases, when the external orifice of the tube was closed

\* The operations on the dogs were performed with the active assistance of G. A. Myamlina, working in our laboratory.




Fig. 1. Insertion of a polyvinylalcohol fistula tube (a) into the left main bronchus (b).

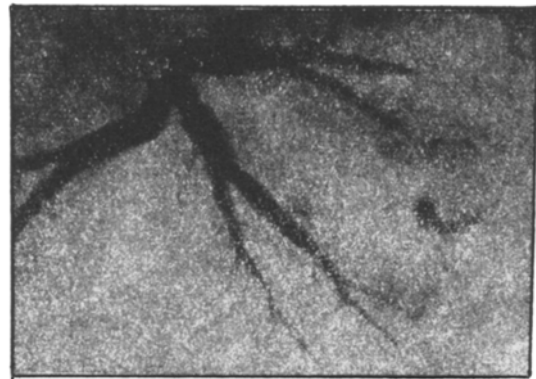

Fig. 2. Postmortem bronchogram of the dog Neron 39 days after operation. Cylindrical bronchiectases in the lobar and segmental bronchus.

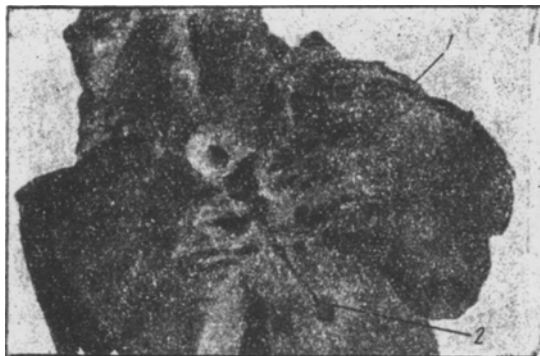

Fig. 3. Dilatation of the lumen of the lobar bronchi (1, 2) in a gross specimen of the lung of the dogs Al'fa (on the 45th day after operation).

with a cork, an obturation atelectasis developed in the lung. Five dogs underwent operation.

From 35 to 45 days after operation, two of the experimental dogs, on which a preliminary vagotomy and stellate ganglionectomy had been done on one side, developed dilatation of the lobar and segmental bronchi, which was found at necropsy and in postmortem bronchograms (Figs. 2 and 3). Postmortem examination of all the dogs showed transpleural fistulae surrounding the plastic tube, in the form of a connective tissue tube. Under these circumstances the layers of pleura were smooth and shiny, with no signs of pathological change. The obstructed lungs were in a state of resorption atelectasis.

By the use of the method described it is possible, in the first place, by closure of the external orifice of the fistula tube, to make continuous observations on areas of atelectasis by the use of bronchography and bacterio-

logical methods; secondly, to introduce into the ligated bronchus various chemical irritants, strains of microorganisms, drugs and so on; and thirdly, to carry out functional investigations (over a long period of time) on a lung isolated from the upper respiratory tract but retaining its nervous and humoral connections with the body as a whole.

#### SUMMARY

A surgical method of formation of a fistula of the main bronchus in dogs was performed by means of a polyvinyl alcohol T-tube. The simultaneous occlusion of the bronchus above the place of fistula formation isolated the lung from the upper respiratory tract.

However, gas exchange functions are maintained through the free external end of the fistula.

This method is of practical use in certain chronic experiments concerned with lung pathology. Bronchitis, atelectasis, bronchiectasis, etc. may be successfully studied in the course of their development by means of bronchography, bacteriology and administration of different substances and drugs through the open end of the fistula.

#### LITERATURE CITED

- [1] M. A. Zakharevskaya, N. N. Anichkov, *Byull. Eksptl. Biol. i Med.*, 32, 10, 321-328 (1951).
- [2] S. A. Reinberg and N. F. Pershina, *Disturbance of Bronchial Patency*, pp.32-64, Moscow, 1946 [In Russian].

- [3] P. Coryllos and G. Birnbaum, Arch. Surg., 1928, N.16.
- [4] G. Delarue and R. Abelaner, Ann. Anat. Path., 1956, N.1.
- [5] G. Lemoine, La thrombose le l'artere bronchique cause de dilatation bronchique chronique de l'adulte. Paris, 1936.
- [6] G. J. Veinberg, J. Thorac. Surg. 1937, No.6.